



PATIENT

Charlie Jones

PRESENTING CLINICAL SIGNS

History: Charlie referred to evaluate a heart murmur. A thyroid level done in October was normal. Charlie is doing well at home with a good appetite and normal activity level. Grade II/VI sternal murmur. BP: 120mmHg x 5. *Sedated with propofol for study

SPECIES

Feline

BREED

DSH

SEX

Female Spayed

AGE

8 years

WEIGHT

11.56lbs

ECHOCARDIOGRAM FINDINGS

2D, m-mode, color flow and Doppler imaging is available.

Left ventricle: The LV diameter is normal with adequate myocardial function. The LV wall thicknesses asymmetric with mild to moderate septal hypertrophy. There is a diffusely hyperechoic endocardium consistent with fibrosis. The papillary muscles are mildly remodeled and hyperechoic.

Left atrium: The left atrium is normal. No obvious spontaneous contrast or thrombi seen.

Mitral valve: The mitral valve is normal in structure and mobility. No obvious systolic anterior motion is seen. No MR.

Aortic valve/Aorta: The aortic valve is normal in morphology and mobility. Normal aortic outflow velocity; laminar flow. No aortic insufficiency.

Right ventricle: Normal right ventricular diameter and morphology indicating no overt evidence of pulmonary arterial hypertension.

Right atrium: The right atrium is normal in dimension.

Tricuspid valve: The tricuspid valve appears normal with no tricuspid regurgitation.

Pulmonic valve/Pulmonary artery: The pulmonic valve is normal in morphology and mobility. No pulmonic insufficiency. Normal RVOT velocity; laminar flow.

Pericardium/other: No pericardial or pleural effusion noted. No obvious cardiac masses.

Heart rhythm: ECG reveals a sinus rhythm with an average HR of 148bpm.

INTERPRETED BY

Maggie Machen
Lamy, DVM
DACVIM (Cardiology)

2-Dimensional Measurements

Ao diam (cm)	0.9
LA diam (cm)	1.2
LA:Ao (Swe)	1.3
IVS thickness (cm)	0.70
LVID diastole (cm)	1.3
PW thickness (cm)	0.40
LVID systole (cm)	0.5
FS (%)	62

Doppler Measurements

PV Vmax (m/s)	0.5
AoV Vmax (m/s)	0.9
MR Vmax (m/s)	NA
TR Vmax (m/s)	NA
TR PG (mmHg)	NA

IMAGING

PERFORMED BY

Pamela Harrigan,
RDCS

HOSPITAL NAME

Mass Veterinary Services

INTERPRETATION OF THE FINDINGS

HCM is a rule out diagnosis, once hypertension and hyperthyroid disease are ruled out. In this normotensive euthyroid cat, primary thickening is suspected. Regardless, the degree of disease is mild, with mild septal thickening and no LA dilation. No cause for the murmur is identified in this study, making it likely physiologic in origin.

REFERRING VET

Dr. Masloski

Prognosis is open, due to the highly variable rates of progression with subclinical feline cardiomyopathy.

INVOICE

27227

DATE

11/1/22



PATIENT

Charlie Jones

SPECIES

Feline

BREED

DSH

SEX

Female Spayed

AGE

8 years

WEIGHT

11.56lbs

INTERPRETED BY

Maggie Machen
Lamy, DVM
DACVIM (Cardiology)

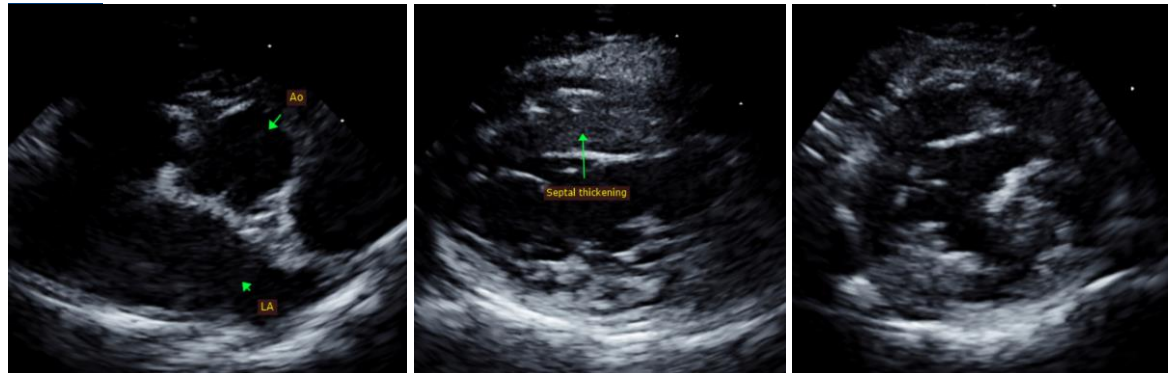
RECOMMENDATIONS

- Given these findings, no medications are indicated.
- Monitor BP and T4 every 6 months.
- Anesthetic risk is considered mild, however judicious IV fluid rates are advised to avoid fluid overload. Additionally, drugs that stimulate heart rate should be avoided unless clinically necessary (glycopyrrolate, atropine). A reasonable protocol includes opioid/benzodiazepine premedication, propofol induction, isoflurane maintenance.
- Risk for complication with steroid use typically follows LA dilation, which in this case is low. That being said, any cat can experience unexpected signs of intolerance and monitoring of RR/RE is advised particularly in the initiation phase.
- Monitor for any clinical evidence of cardiac compromise, including respiratory changes and/or signs of a blood clot event (paralysis, neurologic changes, etc.).

PLAN

- Recommend recheck echocardiogram in 6-12 months to screen for progression, sooner if any clinical signs arise in the interim.

IMAGES



The information and recommendations provided are based on the images presented by the referring veterinarian. No evaluation can be communicated regarding pathology that was not visible in the image/video clips provided.

Thank you for this referral. This report was generated using transcription software, and minor dictation errors may be present. If the clinical or image interpretation does not parallel your findings or if I can be of any further assistance, please contact me.

Maggie Machen Lamy, DVM
Diplomate of the American College of Veterinary Internal Medicine (Cardiology)
info@sonopath.com

Echocardiogram performed by:

Pamela Harrigan, RDCS
Pet Animal Ultrasound Service (4paus.com)

INVOICE

27227

DATE

11/1/22

HOSPITAL NAME

Mass Veterinary Services

REFERRING VET

Dr. Masloski

IMAGING PERFORMED BY

Pamela Harrigan, RDCS